Desordenes vestibulares en el gato

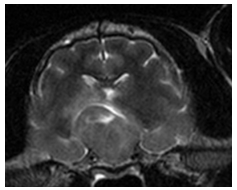

Sergio Rodenas, DVM, MRCVS, Dip ECVN
Especialista europeo reconocido en Neurologia Veterinaria

Facebook Sergio Rodenas Neurologia Neurocirugia veterinaria
Responsable de Neurologia/Neurocirugia Animal Blue Care

Examen neurológico: Aspectos importantes en gatos

1) A veces muy complicado sin sedación
2) En muchos casos tiempo limitado (se cansan)
3) No tomar temperatura, estresarlos, o mirar si tienen dolor antes del examen neurológico que requiera respuestas sensibles
4) Cuantas menos manos o personas mejor
5) Ser selectivo con lo que mas información nos de si el animal esta estresado.

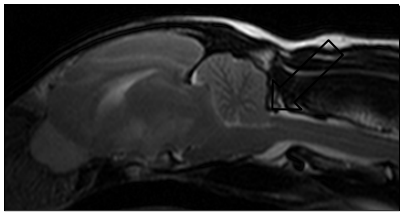

Funciones del sistema vestibular

Sistema sensorial primario (Propiocepcion especial)

-

Mantiene balance y equilibrio en relación con fuerzas gravitacionales

Detecta posición estática de la cabeza, aceleración, deceleración y movimientos rotacionales.

Regula posición de ojos, cuello, tronco y extremidades en relación con los movimientos de la cabeza

- **Vias vestibulo-ocular**
- **Vias vestibulo-espinales**

Desordenes vestibulares en el gato

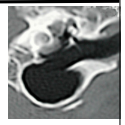

Neuro-anatomia vestibular

Sistema vestibular periférico

- Receptores oído interno
- Ganglio vestibular
- Parte vestibular NC VIII (nervio vestibulococlear)

Sistema vestibular central

- Tronco **encefálico** (médula oblongada rostral/puente)
- Cerebelo (núcleo fastigio y lóbulo floculonodular)

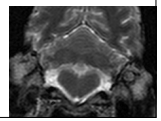

Sistema Vestibular periférico

- Receptores de la información vestibular

Contenidos en el oído interno

Laberinto membranoso y óseo del hueso petroso temporal.

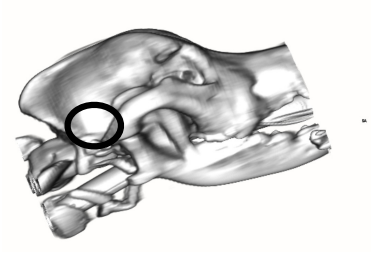

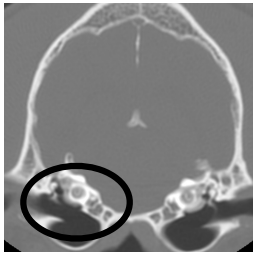

Sistema vestibular periférico

Oído medio

- Membrana timpánica

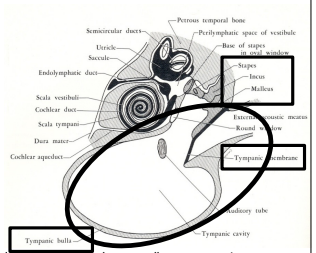

Jenkins; functional mammalian neuroanatomy
Edit 2 Philadelphia

- Bulla timpánica (septum gatos)
Fibras simpáticas, síndrome Horner

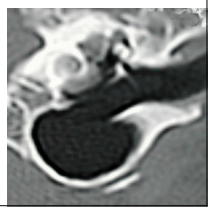

- Osículos auditorios

Sistema vestibular periférico

Oído interno

Laberinto óseo (perilinfa)

Canales semicirculares

Cóclea (audición)

Vestíbulo

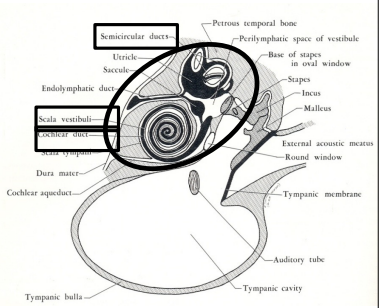

Hueso petroso temporal

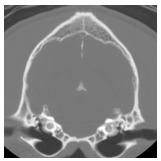

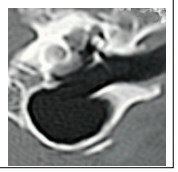

Sistema vestibular periférico

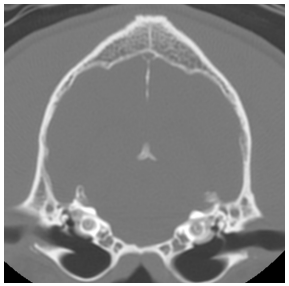

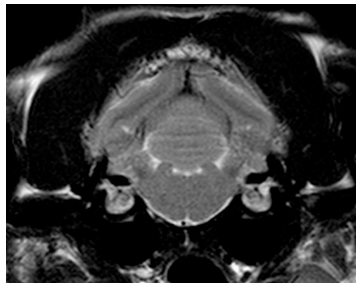

Sistema vestibular periferico

Oido interno

Laberinto membranoso *(endolinfa)*

Coclea

Utriculo/saculo (vestibulo)

Canales semicirculares

Receptores

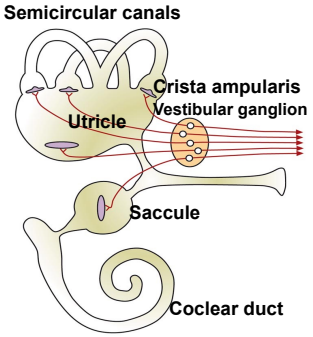

Sistema vestibular periferico

PROPIOCEPTORES

Celulas ciliada en laberinto membranoso (crista ampularis/macual)

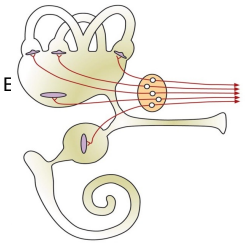

ESTATICA Saculo/Utriculo
- Effecto de gravedad

DINAMICA Canales semicirculares
- Aceleracion angular

Anatomia y fisiologia del Sistema vestibular

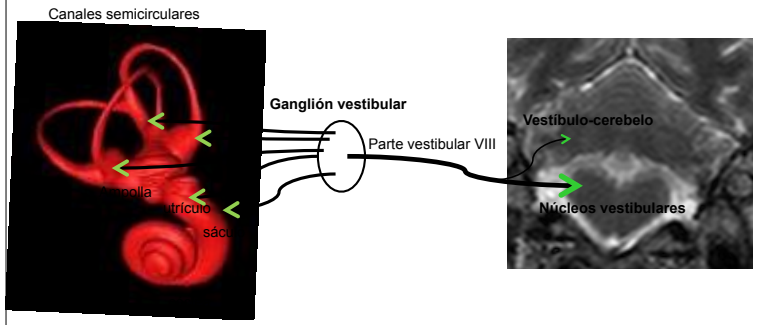

Sistema vestibular periférico

Sistema vestibular central

Desordenes vestibulares en gatos

Sistema vestibular central

Tronco encefalico

1) Médula oblongada rostral

Núcleos vestibulares(4)

2) Puente (parte dorsal)

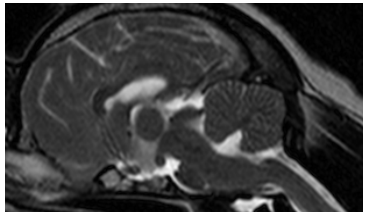

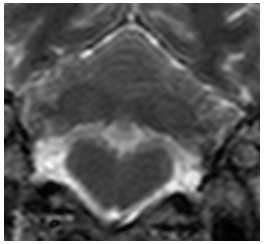

Cerebelo

Vestíbulo cerebelo

Desordenes vestibulares en gatos

Tronco encefalo

Proyecciones medula espinal

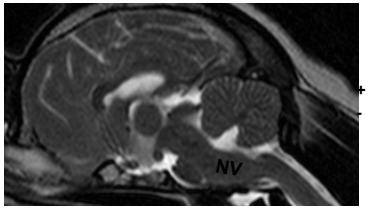

Tracto vestíbulo espinal lateral

Funiculo ipsilateral

+ neuronas ipsilaterales músculos extensores

- Neuronas ipsilaterales músculos flexores

Extensores contralaterales

flexores

extensores

Tracto vestibulo espinal

extensores

flexores

extensores

Tracto vestibuloespinal

Desordenes vestibulares en gatos

Tronco encefalo

Proyecciones medula espinal

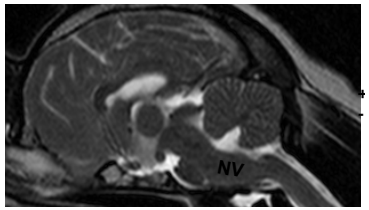

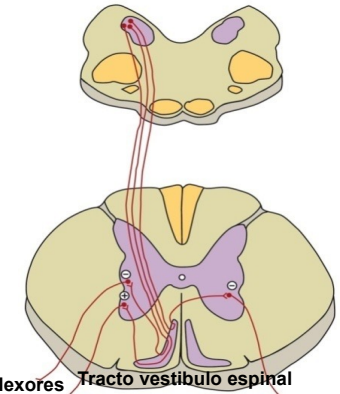

Extensores contralaterales

flexores

extensores

Tracto vestibulo espinal

extensores

Desordenes vestibulares en gatos

Tronco encefalo

Proyecciones tronco encefalico

1) Fascículo longitudinal medial (FLM)

Núcleos motores CN III, IV and VI

Coordina movimientos oculares asociados con cambios en la posición de la cabeza

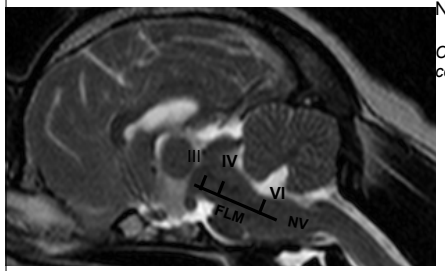

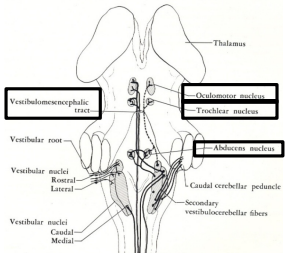

- Trauma craneal; disrupción del FLM
- No reflejo oculocefálico
- Pronóstico grave

Jenkins; functional mammalian neuroanatomy
Edit 2 Philadelphia

Desordenes vestibulares en gatos

Tronco encéfalo

Proyecciones tronco encefalo

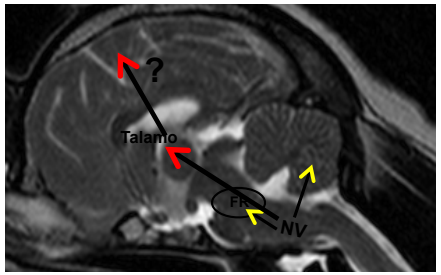

2) Formación reticular
Centro emesis

3) Percepción consciente
Tálamo a corteza cerebral??

Proyecciones cerebelares

Vestíbulo cerebelo

Signos clínicos síndrome vestibular periférico

1) Ataxia vestibular

E

Signos clínicos síndrome vestibular periférico

Ladeo de cabeza

- Perdida de tono muscular musculatura cervica

- Ipsilateral a la lesion

Cabeza rotada, no girada.

- Observar la cabeza en frente del paciente

No ladeo de cabeza

Signos clínicos síndrome vestibular periférico

Estrabismo ventro-lateral

Posicion anormal del globo ocular

- Posicional

Inducido (extension cabeza y cuello)

Ventral a ventro-lateral desviacion del globo ocular exposicion de la esclera.

Ipsilateral a la lesion

- Estrabismos espontaneo o estatico

No vestibular (paralisis NC III, IV y VI)

Vomitos

Signos clínicos síndrome vestibular periférico

Nistagmos

Movimiento involuntario y ritmico de los ojos.

Nistagmo fisiologico (reflejo oculocefalico)

Fase lenta direccion contraria del movimiento de cabeza
fase rapida mismo lado del movimiento.

Preserva la fijacion visual en la retina mientras el cuerpo rota o gira.

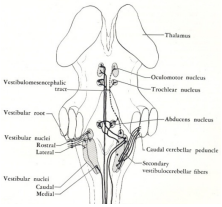

Desordenes vestibulares en gatos

Nistagmos

Nistagmo patologico

Normalmente estimulacion bilateral tonica de las neuronas vestibulares a los nucleos motores de los nervios craneales de los musculos extraoculares.

Perdida de estimulacion tonica en el lado afectado de los nucleos vestibulares, nistagmos.

Posicional (inducidos)

Espontaneos

Sentido del movimiento

Jerk nystagmus (lfase rapida y lenta) → Vertical (central ?)
Rotatorio (central vs periferico)
Horizontal (central vs perifericol)

Nistagmo pendular (no fase rapida ni lenta)
siamese, himalaya (Deficit congenito en vias visuales)

Desordenes vestibulares en gatos

GATOS TUMBARLOS SOBRE LA ESPALDA PARA PROVOCAR NISTAGMO

Signos clínicos síndrome vestibular periférico

Disfuncion del nervio facial

- NC VII entra en el meato acustico interno.
- Dorsal a la bulla timpanica
- Intimo contacto con estructuras vestibulares

Sindrome de Horner

Fibras simpaticas intimo contacto con estructuras oido medio e interno.

- Sindrome ipsilateral
  - Ptosis parpado superior
  - Enoftalmos
  - **Miosis**
  - Protrusion 3 parpado

Enfermedad bilateral vestibular

Movimientos amplios de cabeza
maintener fijacion visual

- No ladeo de cabeza

- Disfuncion facial asociada a veces

P- Ausencia de reflejo oculocefalico
No hay receptores vestibulares funcionales
No estimulos hacia el tronco encefalico
No estimulos a NC extraoculares

- Se caen hacia ambos lados.

Periferico	Central
-Idiopatico	Deficit tiamina/Vit B12
-Toxico	intoxicacion metronidazol
-Idiopatico	Metabolico o toxico
-Otros	inflamatorio

Signos clínicos síndrome vestibular central

- Ataxia

- Estrabismo ventrolateral posicional

- Ladeo de cabeza Ipsi-lateral or contra-lateral a la lesion

- Vomitos

- Chlorpromacina (0.2-0.4 mg/kg/8 horas)
  Diphenhydramina (2-4 mg/Kg/8 horas)
  Meclizina (25 mg/24 horas)
- Ondasetron (cerenia)

Cambios en estado mental

SRAA (Sistema reticular activado ascendente)

Depresion
Estupor
Coma

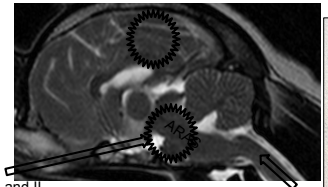

Paresia y deficits en reacciones posturales
Ipsilateral (puente and medula)
Tetra/hemiparesia (Lesion MNS)

Disfuncion de NC → NC VII → CVS/PVS
Disfuncion de NC → NC V-XII → CVS

Desordenes vestibulares en gatos

Signos clínicos	SVC	SVP
Ataxia asimétrica	Si	Si
Ladeo cabeza	Si	Si
Vomito	Si	Si
Nistagmo	Si	Si
- Horizontal /Rotatorio	Si	Si
- vertical	Si	No??
- cambio dirección/posicion cabeza	Si/No	No
- Posicional	Si	Si
- Espontáneos	Si	Si
-Conjugados	Si	Si
-No conjugados	Si	No
Estrabismo posicional	Si	Si
Déficit nervios craneales	Posible V-XII	Posible VII
síndrome Horner	Raro	Posible
Signos cerebelares	Posible	No
Estado mental	Normal /coma	Normal
Reacciones posturales/paresia	Normal /alterado	Normal

Exámenes complementarios

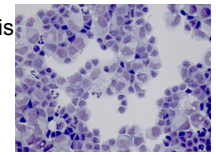

Minimum data base; CBC, biochemistry and urinalysis

Thoracic radiographs and abdominal ultrasound

Otoscopic examination

Thyroid hormones levels

Radiographs tympanic bulla

MRI/CT (MRI more sensitive caudal fossa)

CSF analysis

PCR or serology infectious diseases

BAEP (Brain auditory evoked potentials)

Examenes complementarios

- Analitica completa (hemograma y bioquimica), proteinograma
- FeLV /FIV
- Ecografia abdominal (liquido libre, renomegalia, etc). PIFs Linfomas
- Radiografias de Torax (neoplasia, neumonia, efusion pleural
- Enfermedades infecciosas (Toxoplasma, micoplasma, PIF, etc)

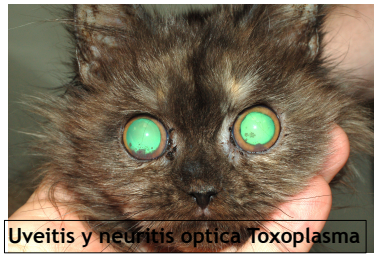

Uveitis y neuritis optica Toxoplasma

Uveitis PIF

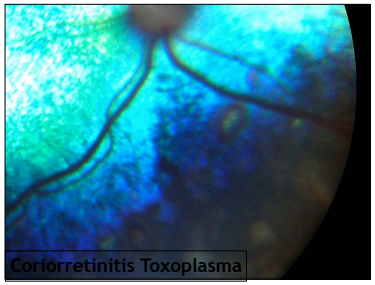

Coriorretinitis Toxoplasma

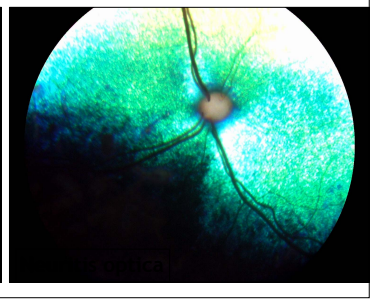

Examenes complementarios

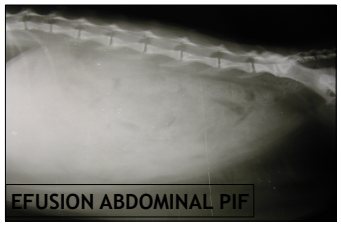

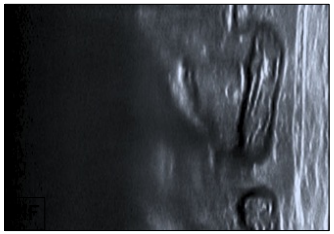

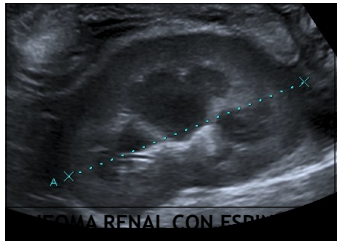

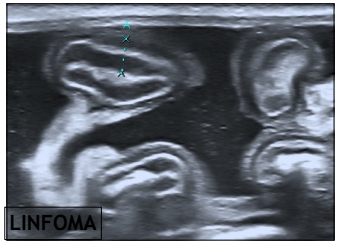

Diagnostico diferencial SVP

Vascular

Inflammatorio/infeccioso(otitis, polipos)

Traumatico/Toxico (aminoglicosidos, clorhexidina)

Anomalia (Enfermedad congenita idiopatica)

E

Metabolico (hipotiroidismo)

Idiopatico (Enfermdad idiopatica vestibular)

Neoplasia/Nutritional

Degenerativo

Diagnostico diferencial SVC

Vascular (ACV, hemorragias)

Inflamatorio/infeccioso (encefalitis)

Traumatico/Toxico (metronidazol)

E Anomalia (quiste aracnoideo, etc)

Metabolico (hipotiroidismo)

Idiopatico

N**eoplasia**/Nutritional (deficit tiamina)

ENFERMEDAD VESTIBULAR PERIFERICA

E

ENFERMEDAD VESTIBULAR PERIFERICA

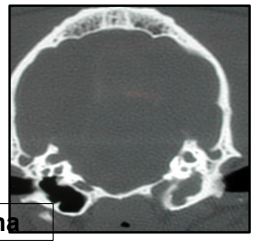

Otitis media/interna

E

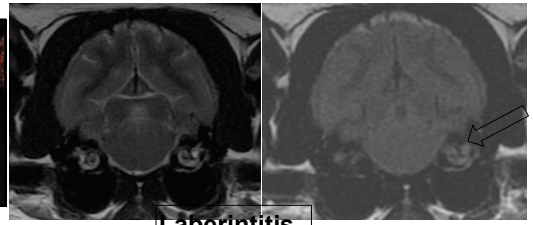

Laberintitis

ENFERMEDAD VESTIBULAR PERIFERICA

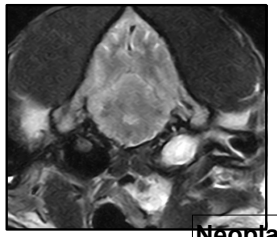

Neoplasia oido interno

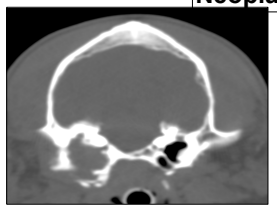

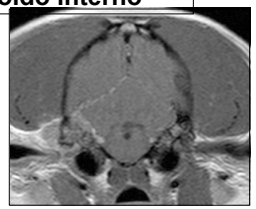

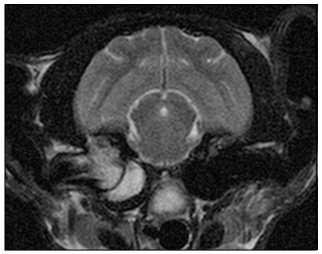

Polipo nasofaringeo

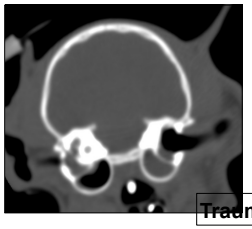

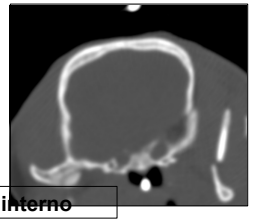

Trauma oido interno

NUTRICIONAL

DEFICIT EN VITAMINA B1/VITAMINA B12

Causas

Comida inapropiada
Insuficiente en dieta comercial
- Dietas ricas en tiaminasas (pescado crudo)

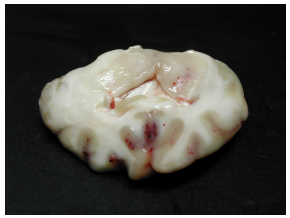

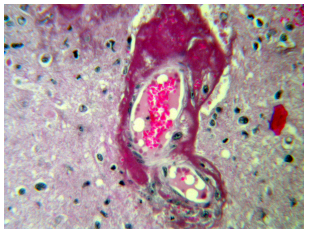

ENFERMEDADES INFLAMATORIAS

- ENFERMEDADES INFECCIOSAS

ENFERMEDADES VIRICAS → **PIF**

PROTOZOARIAS → **Toxoplasma**

BACTERIANA → **Extension otitis**
Absceso epidural

FUNGICAS/PARASITARIAS → **Cuterebra**
Criptococos

- ENCEPHALITIS ORIGEN DESCONOCIDO (INMUNOMEDIADA)

ENFERMEDAD VESTIBULAR CENTRAL

MENINGOENCEFALITIS INFECCIOSA
EMPIEMA POR OTITIS

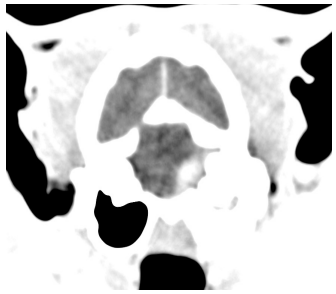

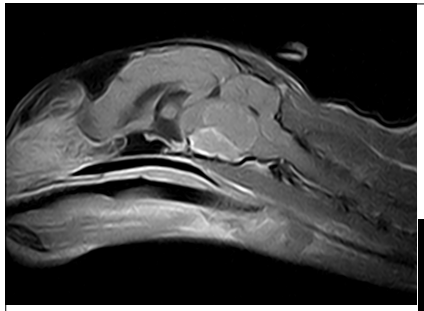

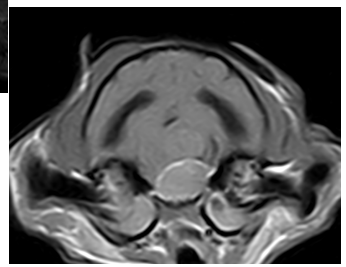

MENINGOENCEFALITIS INFECCIOSA

EMPIEMA POR OTITIS

THEODOR gato 6 meses historia cronica conjuntivitis, uveitis y diarrea

- Peritonitis infeciosa felina (PIF)

- Peritonitis infeciosa felina (PIF)

(coronavirus)

- Mutacion del coronavirus enterico (via mas frecuente a traves de heces)

- Generalmente gatos jóvenes < 3 años (Hasta 15 años descritos)

-1) Forma humeda (poliserositis), efusiones pleural, abdominal
< 9% signos neurológicos

-2) Forma seca (piogranulomatosa)
1/3 gatos signos neurológicos

- 45-50% inflamaciones SNC gatos

-15-20% de todos los casos neurológicos felinos

- Peritonitis infeciosa felina (PIF)

Forma sistemica Puede ir acompañada de las otras formas

anorexia, pérdida peso, diarreas.

Forma ocular

UVEITIS, coriorretinitis, otros signos.

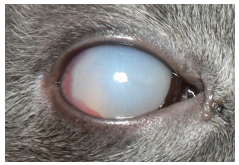

Forma neurológica (multifocal/focal)

Alteración estado mental
Cerebelo/vestibulares
Signos mielopatía (ataxia, paresia)
Convulsiones

- Peritonitis infeciosa felina (PIF)

Diagnóstico TESTS INDIRECTOS

CBC (anemia no regenerativa, leucocitosis)

Bioquímica
Hiperglobulinemia (70% en forma seca)
Gammopatia policlonal, alteraciones renal, hepática

Radiografias torácicas/abdomen (efusiones)

Analisis de las efusiones (exudado inflamatorio)

Citologia del humor acuoso en gatos con uveitis

Deteccion de Ac de Coronavirus (efusiones, sangre, LCR, etc)

Test de Rivalta (exudado en acido acetico), no especifico de PIF

RT-PCR coronavirus en heces

- Peritonitis infeciosa felina (PIF)

Diagnóstico TESTS INDIRECTOS

IMAGEN AVANZADA TAC O RMN

TAC

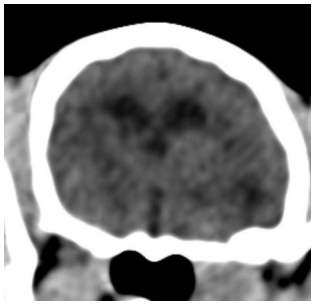

Pre-contraste

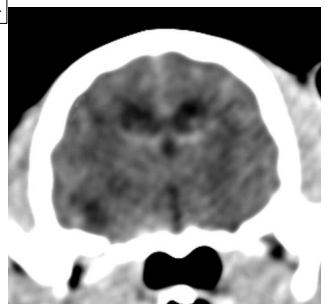

Post-contraste

- Peritonitis infeciosa felina (PIF)

Diagnóstico **RMN** *Cortesia de A Negrin. Dick White Referrals*

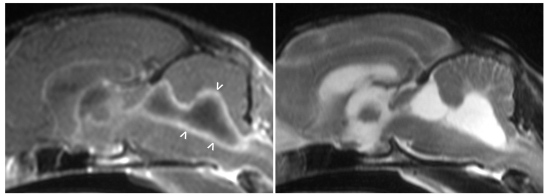

T1 + gadolinium **T2**

LCR

Severa pleocitosis neutrofílica generalmente

Casos descritos con LCR normal

SEROLOGIAS Ac Coronavirus LCR ayuda al diagnostico

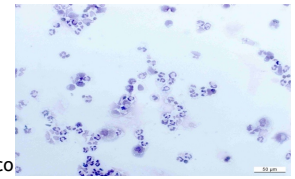

Journal of Feline Medicine and Surgery
1–11

DOI: 10.1177/1098612X16640839
jfms.com
This paper was handled and processed by the European Editorial Office (ISFM) for publication in JFMS
SAGE

Diagnostic utility of cerebrospinal fluid immunocytochemistry for diagnosis of feline infectious peritonitis manifesting in the central nervous system

Stefanie Gruendl[1], Kaspar Matiasek[2], Lara Matiasek[1], Andrea Fischer[1], Sandra Felten[1], Konrad Jurina[3] and Katrin Hartmann[1]

Abstract

Objectives The aim of the study was to evaluate whether an ante-mortem diagnosis of central nervous system (CNS) feline infectious peritonitis (FIP) is possible via immunocytochemical staining (ICC) of feline coronavirus antigen (FCoV) within macrophages of cerebrospinal fluid (CSF).

Methods Prospectively, CSF samples of 41 cats were investigated, including cats with histopathologically confirmed FIP and neurological signs (n = 10), cats with confirmed FIP without CNS involvement (n = 11), cats with neurological signs but another confirmed CNS disease (n = 17), and cats without neurological signs and a disease other than FIP (n = 3). ICC staining of CSF macrophages was performed in all cats. Sensitivity, specificity, positive (PPV) and negative predictive values (NPV) of CSF ICC were calculated.

Results Of 10 samples from cats with CNS FIP, eight had detectable CSF macrophages, seven of which were positive for FCoV. Ten of 11 samples from cats with confirmed FIP without neurological signs had macrophages in the CSF, with all 10 being ICC-positive. In cats with other CNS disorders, 11/17 had macrophages, two of which stained positively. In cats with diseases other than FIP and without neurological disorders, 2/3 revealed macrophages, with one cat showing positive ICC staining. Diagnosis of FIP via CSF ICC had a sensitivity of 85.0% and a specificity of 83.3%. PPV and NPV were 85.0% and 83.3%.

Conclusions and relevance CSF ICC is a highly sensitive test for ante-mortem diagnosis of FIP manifesting in the CNS. However, CNS ICC specificity is too low to confirm FIP and the method should only be applied in conjunction with other features such as CSF cytology. CNS ICC could be helpful to discover pre-neurological stages of CNS FIP.

- Peritonitis infeciosa felina (PIF)

DIAGNOSTICO POST MORTEM en SNC

Exudado e infiltracion piogranulomatosa en plexos coroideos, meninges y parenquima

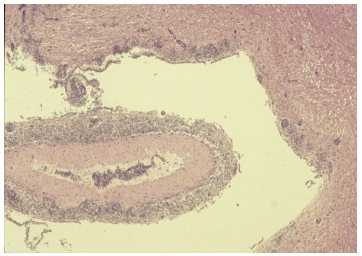

- ANOMALIA CONGENITA

DANDY WALKER

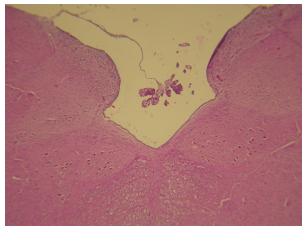

DANDY WALKER

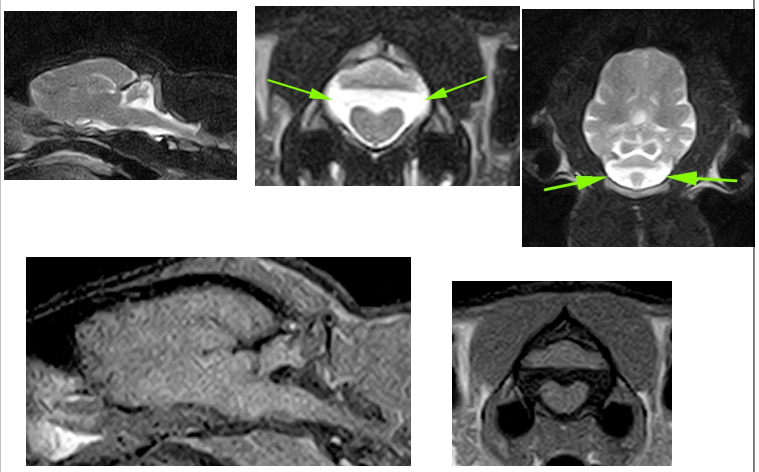

MALFORMACION CHIARI/SIRINGOMIELIA (Chiari-like)

Chiari-like malformation in two cats

S. Minato[1] and M. Baroni

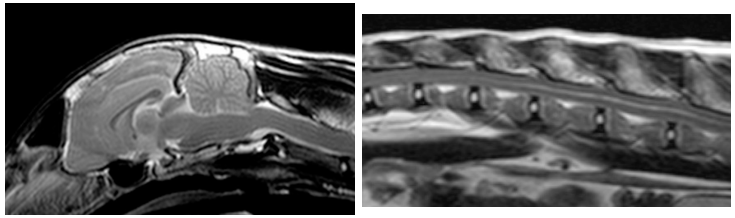

ACCIDENTE CEREBROVASCULAR

MRI and clinical characteristics of suspected cerebrovascular accident in nine cats

Journal of Feline Medicine and Surgery
1–11

DOI: 10.1177/1098612X17723775
journals.sagepub.com/home/jfms
This paper was handled and processed by the European Editorial Office (ISFM) for publication in *JFMS*
SAGE

Danielle E Whittaker, Randi Drees and Elsa Beltran

Abstract

Objectives Cerebrovascular accidents (CVAs) are infrequently reported in cats. To date, clinical characteristics, including lesion localisation and MRI findings, have only been reported in two cats. The aim of the current study is to document MRI findings in cats presenting with CVAs over an 11 year period. Cases were reviewed according to initial clinical presentation, subsequent physical and neurological findings, predisposing systemic disease and short- and long-term (when available) outcome with a view to identifying any typical pattern in disease occurrence.

Methods Patient records of cats presenting to a single referral centre from January 2005 to September 2016 with acute onset, non-progressive (after 24 h) intracranial signs compatible with a CVA and where an MRI was performed within 72 h were retrospectively reviewed.

Results Nine cats met the inclusion criteria. All cats had ischaemic CVAs (presumptively diagnosed in eight cats and confirmed in one cat following post-mortem examination). No cases of haemorrhagic CVAs were identified. Four cats presented with territorial infarcts that were confined to the territory of the rostral or caudal cerebellar arteries (n = 4). Lacunar infarcts were identified in five cats in the location of the cerebrum (n = 1), the thalamus/midbrain (n = 2) and the medulla oblongata (n = 2). Concurrent systemic disease was identified in most (n = 8/9). In the present study short-term prognosis was favourable and 8/9 cats survived to 48 h following admission.

Conclusions and relevance CVAs in cats occur in the same vascular territories as in dogs and have similar MRI features. This study notes that the presenting cats had a high likelihood of concurrent disease (8/9 cases) but had a favourable short-term prognosis, if neither the clinical presentation nor concurrent disease were severe.

ACV ISQUEMICOS DIAGNOSTICO POR IMAGEN

RESONANCIA MAGNETICA NUCLEAR

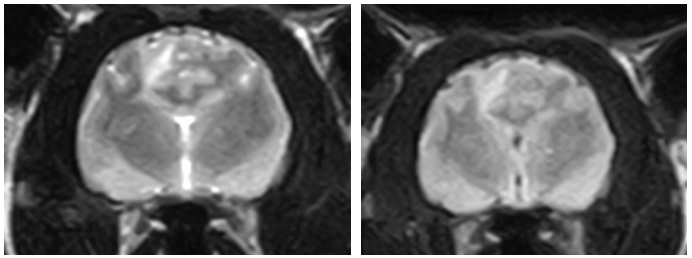

INFARTO ARTERIA CEREBRAL ROSTRAL IDIOPATICO

Cortesia de A Negrin. Dick White Referrals

ACV ISQUEMICOS DIAGNOSTICO POR IMAGEN

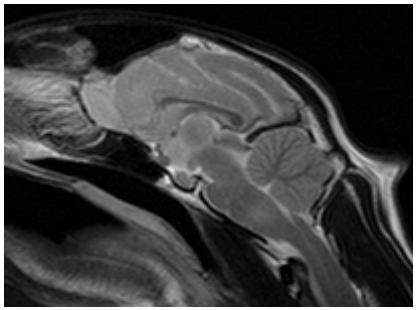

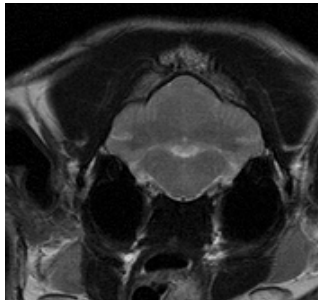

Infarto arterias perforantes en gato

HIPERTENSION IDIOPATICA

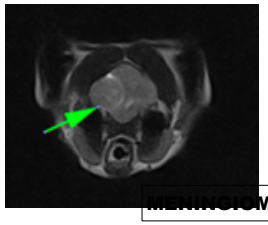

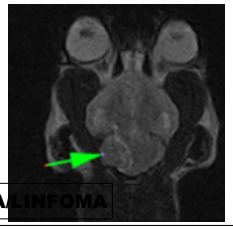

MENINGIOMA/LINFOMA

NEOPLASIA INTRACRANEALES

Tumores intracraneales especie felina

J Vet Intern Med 2003;17:850–859

Feline Intracranial Neoplasia: Retrospective Review of 160 Cases (1985–2001)

Mark T. Troxel, Charles H. Vite, Thomas J. Van Winkle, Alisa L. Newton, Deena Tiches, Betsy Dayrell-Hart, Amy S. Kapatkin, Frances S. Shofer, and Sheldon A. Steinberg

The purpose of this study was to determine the frequency of different tumor types within a large cohort of cats with intracranial neoplasia and to attempt to correlate signalment, tumor size and location, and survival time for each tumor. Medical records of 160 cats with confirmed intracranial neoplasia evaluated between 1985 and 2001 were reviewed. Parameters evaluated included age, sex, breed, FeLV/FIV status, clinical signs, duration of signs, number of tumors, tumor location(s), imaging results, treatment, survival times, and histopathologic diagnosis. Most of the cats were older (11.3 ± 3.8 years). Primary tumors accounted for 70.6% of cases. Metastasis and direct extension of secondary tumors accounted for only 5.6 and 3.8% of cases, respectively. Twelve cats (7.5%) had 2 or more discrete tumors of the same type, whereas 16 cats (10.0%) had 2 different types of intracranial tumors. The most common tumor types were meningioma (n = 93, 58.1%), lymphoma (n = 23, 14.4%), pituitary tumors (n = 14, 8.8%), and gliomas (n = 12, 7.5%). The most common neurological signs were altered consciousness (n = 42, 26.2%), circling (n = 36, 22.5%), and seizures (n = 36, 22.5%). Cats without specific neurological signs were common (n = 34, 21.2%). The tumor was considered an incidental finding in 30 (18.8%) cats. In addition to expected relationships (eg, meninges and meningioma, pituitary and pituitary tumors), we found that lesion location was predictive of tumor type with diffuse cerebral or brainstem involvement predictive of lymphoma and third ventricle involvement predictive of meningioma.

Key words: Brain tumor; Cat; Diagnosis; Glioma; Lymphoma; Meningioma.

NEOPLASIA INTRACRANEALES

Tumores intracraneales especie felina

Incidencia 3.5/100.000 gatos *Vandevelde et al. Brain tumors in domestic animal.1984*

Hasta 2.6% *Zaki et al JASP 1976*

Distribución

Primarios (70.6%)
- Meningiomas
- Gliomas
- Otros

Secundarios (29.4%)
- Linfomas
- Tumores pituitarios
- Otros

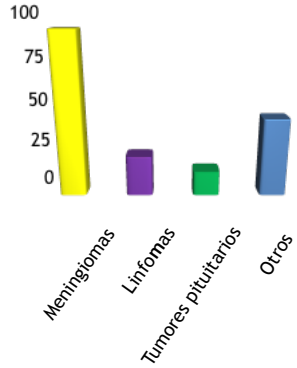

Conclusiones

Vestibular??

Partial seizures, syncope, myasthenia gravis, others

Diferencia entre SVP u SVC

Factor pronostico

Vestibular es un sindrome (NO ENFERMEDAD)

Muchos perros con SVC no signos claros (imagen indicada)

MUCHAS GRACIAS

Preguntas ?